

4-28-2023

Treatment of Gingival Fenestration using Mucoperiosteal Flap with Connective Tissue Graft: A Report of Two Cases

Swati Jaglan

Department of Periodontics, Post Graduate Institute of Dental Sciences, Rohtak, Haryana, India,
swatijaglan2018@gmail.com

Shikha Tewari

Department of Periodontics, Post Graduate Institute of Dental Sciences, Rohtak, Haryana, India,
drshikhatewari@yahoo.com

Follow this and additional works at: <https://scholarhub.ui.ac.id/jdi>



Part of the [Dental Hygiene Commons](#), [Dental Materials Commons](#), [Endodontics and Endodontology Commons](#), [Health Economics Commons](#), [Oral and Maxillofacial Surgery Commons](#), [Oral Biology and Oral Pathology Commons](#), [Orthodontics and Orthodontology Commons](#), [Pediatric Dentistry and Pedodontics Commons](#), and the [Periodontics and Periodontology Commons](#)

Recommended Citation

Jaglan, S., & Tewari, S. Treatment of Gingival Fenestration using Mucoperiosteal Flap with Connective Tissue Graft: A Report of Two Cases. *J Dent Indones.* 2023;30(1): 52-56

This Case Report is brought to you for free and open access by the Faculty of Dentistry at UI Scholars Hub. It has been accepted for inclusion in *Journal of Dentistry Indonesia* by an authorized editor of UI Scholars Hub.

Treatment of Gingival Fenestration using Mucoperiosteal Flap with Connective Tissue Graft: A Report of Two Cases

Cover Page Footnote

CONFLICT OF INTEREST Authors report no conflict of interest.

CASE REPORT

Treatment of Gingival Fenestration using Mucoperiosteal Flap with Connective Tissue Graft: A Report of Two Cases

Swati Jaglan, Shikha Tewari*

Department of Periodontics, Post Graduate Institute of Dental Sciences, Rohtak, Haryana, India
**Correspondence e-mail to: drshikhatewari@yahoo.com*

ABSTRACT

Fenestration term is derived from the Latin word 'fenestra' means 'window'. Gingival fenestration is not found in routine while its actual occurrence is assumed to be higher. Additionally, if these mucogingival defects persist for a longer duration it may lead to adverse outcomes like compromised esthetics, hypersensitivity, plaque and calculus deposition, and susceptibility to dental caries. Present cases of gingival fenestration were successfully treated by using full-thickness flap elevation with connective tissue graft placement. Two cases were presented with the accumulation of plaque and calculus and having gingival fenestration to the respective sites. After phase I therapy, full thickness flap was raised and a connective tissue graft was placed beneath the fenestrated area. The successful results were obtained in both cases in terms of complete closure of gingival fenestration defects and well-adapted margins with adjacent tissues at one year of follow-up. Full thickness flap with connective tissue graft procedure resulted in complete closure of gingival fenestration in both cases with no recurrence at one-year follow-up and can be used as a successful and predictable treatment modality for the management of such cases.

Key words: connective tissue, fenestration, gingiva, reconstructive surgical procedure, wound healing

How to cite this article: Jaglan S, Tewari S. Treatment of gingival fenestration using mucoperiosteal flap with connective tissue graft: A report of two cases. *J Dent Indones.* 2023;30(1):52-56

INTRODUCTION

Gingival fenestration (GF) is a gingival defect wherein there is display of tooth root surface because of loss of the overlying bone and gingiva.¹ There are various factors which are linked with these defects including plaque/calculus deposits, trauma, cervical enamel projections, tooth malalignment, occlusal factors, spurious habits and iatrogenic factors.^{2,3} Root surface exposed due to GF may result in difficulty in plaque control, susceptibility for dental caries, hypersensitivity and compromised aesthetics.⁴ Techniques used to correct GFs include modified pouch and tunnel technique, reverse partial thickness flap⁵ and modified papilla preservation flap using connective tissue graft (CTG).² Double pedicle flap technique using dehydrated amnion-chorion membrane (dHACM)⁶ and gingivectomy with gingivoplasty⁷ are also employed for GF closure. Thin periodontal phenotype usually associated with mandibular teeth adds complexity during surgical intervention and affects the treatment outcome. Therefore, a simple approach was planned to correct GFs in mandibular teeth by using full thickness flap with connective tissue graft placement.

CASE REPORT

Case 1

A systemically healthy 17-year-old male patient with no history of smoking, reported with chief complaint of bleeding gums and foul smell from mouth for four months. On intraoral examination inflammatory enlargement of gingiva with abundance of plaque and calculus was observed, and presence of a thin eroded area in keratinized tissue with respect to mandibular anterior buccal region of left central incisor was noted (Figure 1A). On the recall visit after 2 weeks following scaling, a GF measuring 2mm length ×2mm width on the mid-buccal surface of mandibular left central incisor approximately 3mm apical to gingival margin was detected (Figure 1B). Pockets with depths of 3-4mm in the interdental areas with attachment loss and 1mm sulcus depth without attachment loss at the mid-buccal aspect were also noted. On radiographic examination using gutta percha insertion through thin eroded area it was found that there was no periapical tissues involvement, but there was some loss of coronal portion of the alveolar crest with respect to the fenestration defect and adjacent areas (Figure 1C). After completion of the initial phase I therapy and

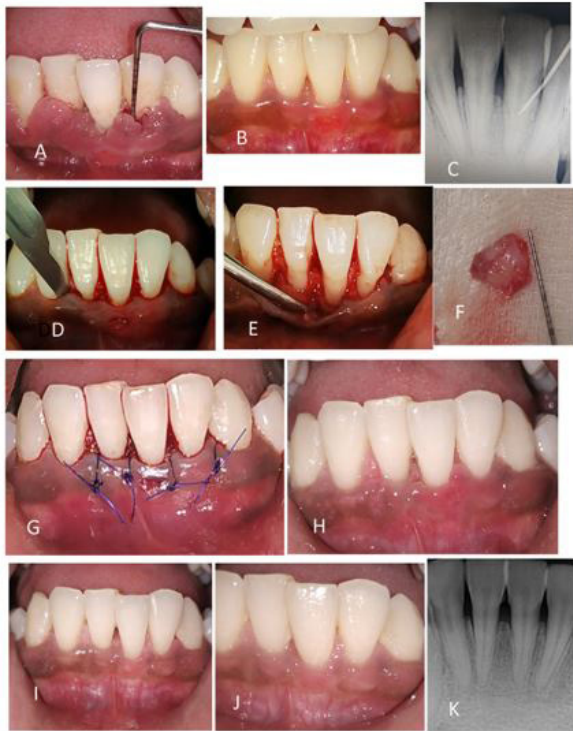

Figure 1. Case 1: Technique of gingival fenestration closure around mandibular left central incisor. (A) Pre-operative photograph showing abundance of plaque and calculus with inflamed and enlarged gingiva. (B) After completion of phase 1 therapy well-defined thin eroded area was evident over mid-buccal aspect of mandibular left central incisor. (C) Radiograph showing insertion of gutta percha point to detect any apical extension. (D) Intra-crevicular incision given and a well-defined gingival fenestration with respect to mid-buccal aspect of mandibular left central incisor. (E) After flap reflection complete dehiscence of bone was present. (F) Connective tissue graft harvested. (G) Placement of interrupted sutures after graft placement. (H) Follow up after 2 weeks. (I) Follow up after 6 months. (J) Follow up after 1 year. (K) Radiograph of treated site after 1 year follow up period.

resolution of inflammation, it was decided to treat the defect with a surgical approach.

After taking verbal and written consent from patient/guardian surgical procedure was started. In this case supra-periosteal incision could not be given because of marginal bone loss and very thin/fragile gingival tissue present surrounding the fenestrated area. So, a full thickness flap elevation with CTG was planned for gingival fenestration closure. After achieving local anaesthesia in the surgical area from mesiobuccal line angle of right mandibular to mesiobuccal line angle of left mandibular canine, intra-crevicular incision was given extending one adjacent teeth mesial and distal to the fenestration defect. A full thickness flap was elevated till the bone exposure of upto 3-4 mm and thorough debridement of root surface was done (Figure 1D and E). Bone dehiscence was evident in this case. A 2mm thick connective tissue graft with size 3 times of dimension of fenestration defect

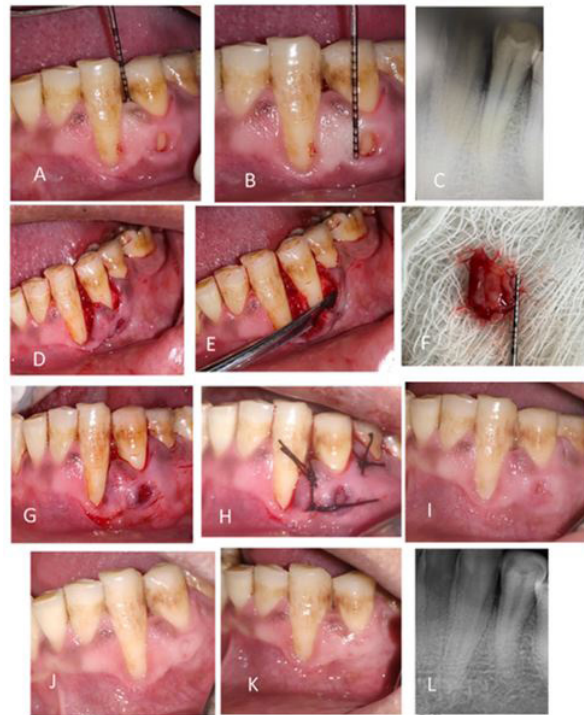


Figure 2. Case 2: Technique of gingival fenestration closure around mandibular left first premolar. (A) Pre-operative photograph showing well distinct gingival fenestration with respect to mandibular left first premolar with interdental pocket depth of 3-4mm. (B) Dimension of gingival fenestration was approximately 3×2mm. (C) Radiograph showing crestal bone loss at mesial aspect of first premolar. (D) Intra-crevicular incision. (E) Reflection of full thickness flap. (F) Connective tissue graft harvested. (G) CTG was placed beneath the gingival fenestration. (H) Placement of interrupted suture interproximally and one holding suture at apical aspect of GF. (I) Follow up after 2 weeks. (J) Follow up after 6 months. (K) Follow up after 1 year. (L) Radiograph of treated site after 1 year follow up period.

was harvested from the palate using single incision technique⁸ (Figure 1F) and placed partially over the avascular area of root surface and partially on the bone surface underneath the fenestration. Interrupted suturing technique (using suture material 4-0 prolene, Ethicon, Johnson&Johnson Pvt Ltd. India) was used to secure the flap in position (Figure 1G). Post-operative instructions and prescription of amoxicillin 500 mg thrice a day for 5 days⁹ and Ibuprofen 400 mg thrice a day for 3 days were given to the patient.⁹ Use of a 0.2% Chlorhexidine mouthwash twice daily for a period of 2 weeks was also prescribed.¹⁰ Suture removal was done after 10 days. Patient was recalled after one month of suture removal for follow up and after that every 3 months subsequently for one year. (Figure 1H-K).

Case 2

A 30 year old systemically healthy male patient with history of past smoking, presented with chief complaint of esthetic disfigurement in mandibular

left canine and premolar region from past 6 months. Patient's occupation history revealed that he works in a tool making factory and has a habit of holding iron nails by his teeth. On intraoral examination a well distinct gingival fenestration of approximately 3mm length ×2mm width was found with respect to mandibular left first premolar and a gingival recession with respect to mandibular left canine was also noted (Figure 2A and B). Patient was willing for closure of gingival fenestration defect only in premolar region. On radiographic examination crestal alveolar bone loss with respect to mesial and distal aspect of premolar was found (Figure 2C). In case-2 gingival recession present on canine was very large in dimensions, so supra-periosteal incision could not be given properly as the gingival tissue was less on mesial side of first premolar for tunnel preparation. Further, patient did not want recession coverage in canine. The dimension of recession on canine was large and cannot be corrected in single surgery along with the correction of fenestration. This may require a second stage surgery. Therefore, a full thickness flap elevation with connective tissue graft placement with respect to defect for fenestration closure was decided, after obtaining written and verbal consent from the patient. After completion of Phase I therapy, patient was recalled for surgical management of GF. After attaining local anaesthesia to circumscribed area extending from apical end of mesiobuccal line angle of mandibular left canine to mesiobuccal line angle of mandibular left second premolar, an intra-crevicular incision was given using 15 no. blade extending mesial to distal aspect of defect site. A full thickness flap was elevated using periosteal elevator exposing 3-4 mm of marginal bone surface and area was debrided with surgical curettes to remove any granulation tissue and any root surface irregularities (Figure 2D and E).

A connective tissue graft of 3 times of fenestration dimensions and 2 mm of thickness was harvested, using a template which was placed on donor area to mark the extent of graft. Single incision technique⁸ was used and incision was given from right side of palatal aspect extending 2 mm away from marginal gingiva toward mid-palate continued from mesio-palatal line angle of first premolar to mesio-palatal line angle of first molar. The procured CTG was placed underneath the defect area on the avascular root surface (Figure 2F and G). Size of graft was decided on the basis of size of fenestration defect and surrounding fragile gingival tissue. CTG was placed beneath the fenestrated defect to close the fenestration defect and to provide strength to surrounding fragile tissue. Adequate size of CTG is also required for maintaining the blood supply of graft from the lateral and apical side of fenestration defect. Flap was repositioned and secured with sutures (4-0 black silk, TRUSILK, Healthium Medtech Private Limited, India) using interrupted suturing technique (Figure 2H). Post-operative instructions included to avoid hot liquid/food, citrus fruits/highly spiced foods during the first 24 hours, refrain of brushing over

operated area and avoid any exertion exercises for few days after surgery. Patient was recalled after 10 days for suture removal. Drugs prescribed were amoxicillin 500 mg thrice a day for 5 days⁹ and Ibuprofen 400 mg thrice a day for 3 days.⁹ Use of a 0.2% Chlorhexidine mouthwash twice daily for a period of 2 weeks was also prescribed.¹⁰ After suture removal patient was recalled at 1 month interval followed by after every 3 month upto 1 year (Figure 2I-L).

Treatment outcome

A complete closure of defect with progressive tissue maturation throughout the follow-up period of 1 year and uneventful healing was noted in case-1 (Figure 1A, B, G, H, I and J) and case-2 (Figure 2A, G, H, I, J and K). Patient experienced slight discomfort in the form of mild pain at the donor site in case-2, which was subsided within a week.¹¹ This minimal morbidity post operatively in single incision technique after harvesting connective tissue graft from palate is common.

DISCUSSION

In first case etiologic factor was abundance of plaque and calculus, that led to inflammatory changes which persisted for a long period of time. Inflammatory changes led to gingival fenestration on attached gingiva. Marginal gingiva was not receded apically and at the enamel junction on mandibular left central incisor tooth (Figure.1B and G). While in second case it may be due to prominent position of tooth root in dental arch with repeated mechanical trauma via iron nails due to patient habit.⁴ The surgical approach used in present case report is simple as full thickness flap was reflected, and cost-effective as autogenous CT graft was used as compared to the use of expensive acellular dermal matrix grafts and dehydrated amnion-chorion membrane.

The previous studies reported in literature to treat gingival fenestration have used partial thickness flap, dehydrated amnion-chorion membrane (dHACM), pouch and tunnel technique with connective tissue graft described in Table 1 along with their advantages and disadvantages. Use of dehydrated amnion-chorion membrane (dHACM) is limited in cases where thin phenotype and lack of keratinized tissue is present and need of phenotype modification is primary concern. In the present cases, there was difficulty in reflecting split-thickness flap in the gingival fenestration area due to thin and fragile gingiva in surroundings of GF, and such flap may have resulted in further increase in size of fenestration. In this case report, gingival fenestration defects were successfully treated using surgical approach of full thickness flap in combination with connective tissue graft in mandibular teeth with no recurrence. Avascular root surface beneath the thin friable tissue at fenestration site limit the healing of gingival fenestration by primary intention. Therefore

Table 1. Studies reported in literature to treat gingival fenestration.

Author	Type of study	Location of GF	Gingiva involved	Etiology of GF	Procedure	Reoccurrence (yes/no)	Follow-up time	Advantages	Disadvantages of procedure used
Pendor et al ⁴	A case-report	Mandibular left lateral incisor	Attached gingiva	H/o gutka chewer	Modified pouch and tunnel technique with connective tissue graft	No	6 months	Extension of corono-apical releasing incisions was kept minimum to facilitate accessibility without involving marginal gingiva, improve blood supply to graft and reducing patient morbidity	Primary coverage could not be achieved in a small area, mid-labially and one cannot preclude the possibility of secondary coverage that occurs by creeping attachment
Kita et al ⁵	A case-report	Mandibular right central incisor	Attached gingiva extending to muco-gingival junction	Dental plaque, occlusal interference at anterior guidance	A reversed partial thickness flap with connective tissue graft	No	6 months	Coronal extension of releasing incisions was kept to a minimum to facilitate access without involving the gingival margin or papilla which leads into minimum post-operative failure in esthetics due to necrosis	Potentially negative effect of horizontal incisions. Although not evident on due to short duration of follow-up period.
Haskell B et al ²	A case-report	Maxillary left canine	Attached gingiva	Sharp mechanical etiology (abfraction)	Modified papilla preservation flap with connective tissue graft with odontoplasty	No	18 months	CTG gold standard for long-term stability, tissue thickening and ability to remain exposed as compared to acellular dermal matrix graft	Exposure of alveolar crest leads into future bone loss although it's not evident practically.
Bhide et al ⁶	A case-report	Maxillary right canine	Attached gingiva		A double pedicle flap approach via split thickness flap and dehydrated amnion-chorion membrane (dHACM)	No	15 months	Muco-periosteal flap reflection provide adequate visual and surgical field to perform odontoplasty	Very costly procedure Split thickness flap is very difficult to carry out in thin gingival phenotype
Kajimoto et al ⁷	A case-report	Mandibular left central incisor	Attached gingiva		Gingivectomy and gingivoplasty	No	8 years	dHACM is derived from human placental tissue, which is considered to be "immunoprivileged", and so can be transplanted to non-identical recipients with very minimal rejection-related inflammation at the surgical sites, does not need additional stabilization because it adapts intimately over the defect area, contain benefit of occlusive barrier membrane and a good carrier of various growth factors. Easy to perform	Esthetic may be compromised in cases where marginal gingiva at normal position

full thickness flap and placement of CT graft beneath the GF was carried out. A careful evaluation of etiologic factors, placement of connective tissue graft partially on bone surface at the apical end and lateral side to maintain the blood supply of the CTG with adequate connective tissue graft size and thickness were the keys to successful management of these cases.

CONCLUSION

A complete closure of margins without any recurrence of the affected areas in both cases was obtained in 1 year follow-up period in the current case report. Patients were highly satisfied with the results.

CONFLICT OF INTEREST

Authors report no conflict of interest.

REFERENCES

1. Lane JJ. Gingival fenestration. *J Periodontol.* 1977; 48(4):225-7.
2. Haskell B, Stern JK, Ghiassi J, Kurialacherry A, Gaud-Quintana S, Peacock ME. Resolution of abfraction-associated gingival fenestration utilizing connective tissue grafting. *Case Rep Dent.* 2019; 2019:6810670.
3. Gandi P, Anumala N, Reddy A, Chandra RV. A regenerative approach towards mucosal fenestration closure. *BMJ Case Rep.* 2013; 2013:bcr2013009604.
4. Pendor S, Baliga V, Muthukumaraswamy A, Dhadse PV, Ganji KK, Thakare K. Coverage of gingival fenestration using modified pouch and tunnel technique: A novel approach. *Case Rep Dent.* 2013; 2013:902585.
5. Kita D, Kinumatsu T, Ishii Y, Yamanouchi K, Saito A. Treatment of gingival fenestration with connective tissue graft: A case report. *Bull Tokyo Dent Coll.* 2018; 59(2):111-9.
6. Bhide VM, Tenenbaum HC. Treatment of gingival fenestration with a double pedicle flap approach and dehydrated amnion-chorion membrane: A case report. *Clin Adv Periodontics.* 2020; 10(4):200-3.
7. Kajimoto NC, Buischi YP, Loomer PM, Pola NM, Nagata MJH, Bosco AF. Gingival fenestration defect treated with gingivectomy and gingivoplasty: A case report with an 8-year follow-up. *Clin Adv Periodontics.* 2021; Epub ahead of print.
8. Hürzeler MB, Weng D. A single-incision technique to harvest subepithelial connective tissue grafts from the palate. *Int J Periodontics Restorative Dent.* 1999; 19(3):279-87.
9. Tewari S, Dhiman M, Bhagavatheeswaran S, Thakur V, Tewari S. Management of isolated labial mucosal fenestration by endodontic microsurgery along with platelet-rich fibrin and connective tissue graft: A series of four cases. *Clin Adv Periodontics.* 2022; 12(3):194-203.
10. Mehta L, Tewari S, Sharma R, Sharma RK, Tanwar N, Arora R. Assessment of the effect of orthodontic treatment on the stability of pre-orthodontic recession coverage by connective tissue graft: A randomized controlled clinical trial. *Quintessence Int.* 2022; 53(3):236-48.
11. Liu CL, Weisgold AS. Connective tissue graft: A classification for incision design from the palatal site and clinical case reports. *Int J Periodontics Restorative Dent.* 2002; 22(4):373-9.

(Received July 27, 2022; Accepted March 6, 2023)