

Closure of Oroantral Communication with Gelfoam and Collagen Membrane after Periapical Cyst Enucleation- A Case Report

A SENTHIL KUMAR¹, C PRASAD², DAVIDSON RAJIAH³, P KAMALAKANNAN⁴, S PRAVEEN KUMAR⁵

ABSTRACT

Periapical cyst is the most common inflammatory cyst that occurs in jaw bones. Epithelial cell rests of Malassez in periodontal ligaments are the main cause for the periapical cysts to be formed. Periapical cyst occurs commonly in infected and necrotic periapical area, with male sex predilection and occurs, especially in the 3rd to 6th decades of life. Non vital tooth left untreated for long time predisposes to periapical cyst formation. Oroantral Communication (OAC) is one of the most routinely encountered complications during surgical procedure by oral and maxillofacial surgeons when attempting to remove a cyst from maxilla. Oroantral communication is the abnormal, pathologic, unnatural open connection between the oral cavity and maxillary sinus. If such a communication remains open it can cause ingress of microorganisms from the oral cavity into the antrum resulting in maxillary sinusitis, and develops into an Oroantral Fistula (OAF). Hereby, authors presented a case report of a 32-year-old female patient with the complaint of pain and swelling in relation to the left upper back tooth region. The gelfoam and collagen membrane were used to close an oroantral communication, which was developed after periapical cyst enucleation.

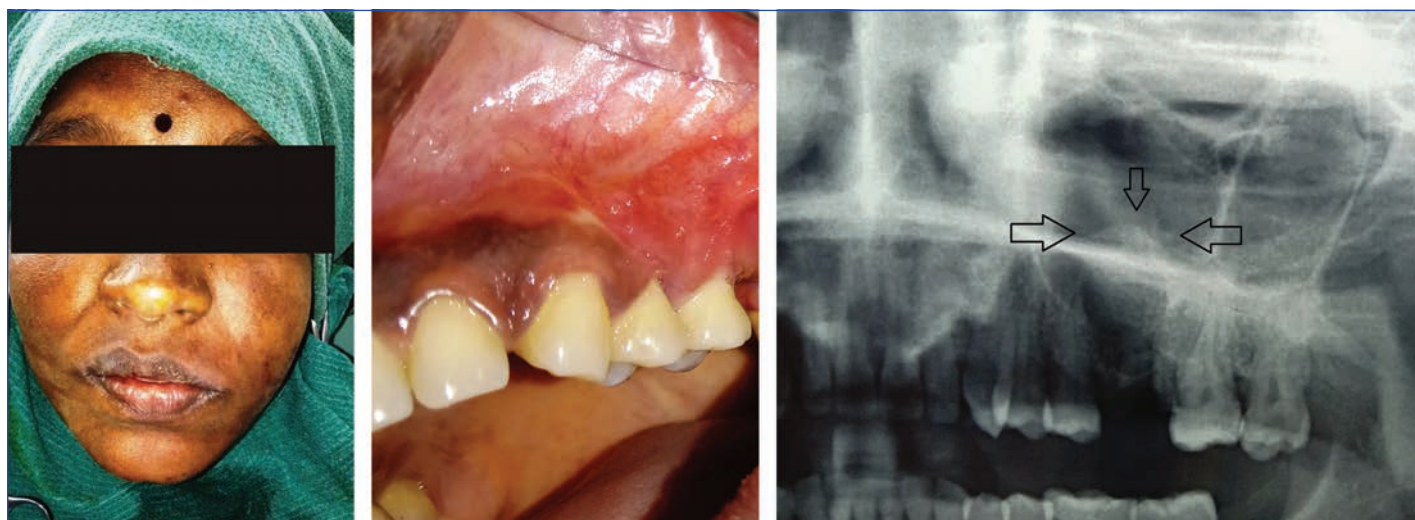
Keywords: Allograft, Fistula, Keratocyst, Maxillary sinusitis, Radicular cyst

CASE REPORT

A 32-year-old female patient reported to the Department of Oral and Maxillofacial Surgery with the complaint of swelling in relation to the left upper back tooth region for past three months and also complained of pain in left upper back tooth region for the past one month ago [Table/Fig-1]. History of present illness revealed that the patient had history of pain in left maxillary first molar (26) root stump due to dental caries, unnoticed for several years. She developed small swelling 3 months back with mild pain and swelling gradually increasing in size. On extraoral examination, swelling had ill-defined borders, normal in colour, soft in consistency and warm in palpation. On intraoral examination, the swelling obliterated buccal vestibule region extending from 24, 25, 26 teeth, with normal mucosal colour, no pus exudation, soft in consistency, no egg shell crackling. The tooth 25 was vital by pulp vitality test and 26 was non vital root stump which was tender on percussion and the palatal region was

devoid of any swelling or sinus tract [Table/Fig-2]. She developed pain occasionally which was relieved by analgesics. Medical history and surgical history were not significant. Personal history showed that, she was brushing her teeth once daily with no habit of chewing tobacco. Cervical Lymph nodes were non palpable. Based on the history and clinical examination, the following differential diagnoses were made-periapical cyst, dentigerous cyst, ameloblastoma, odontogenic keratocyst, periapical cementoma and Pindborg tumour.

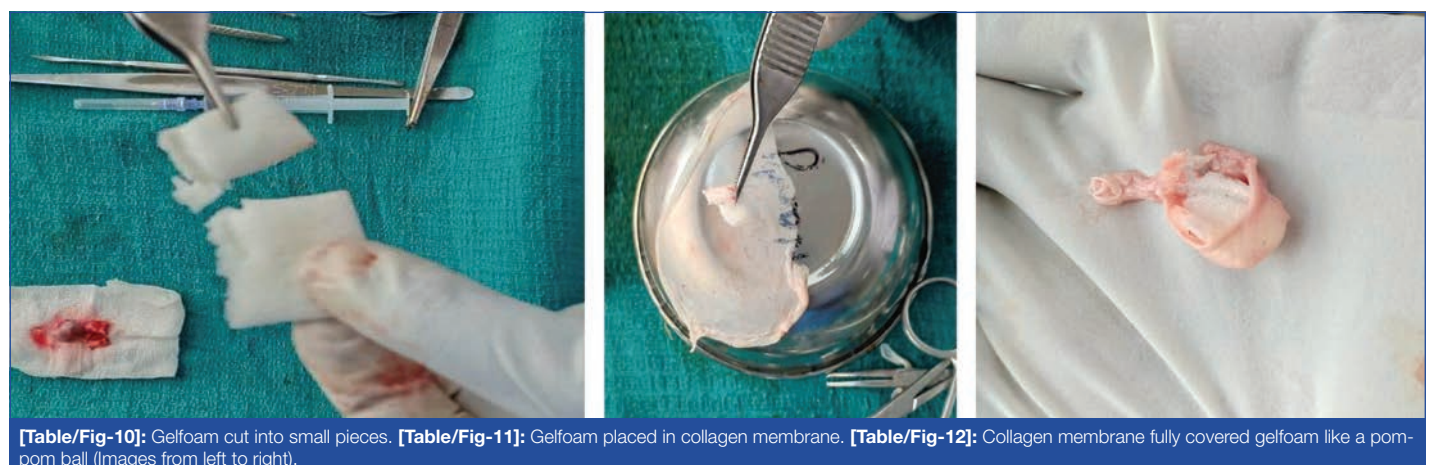
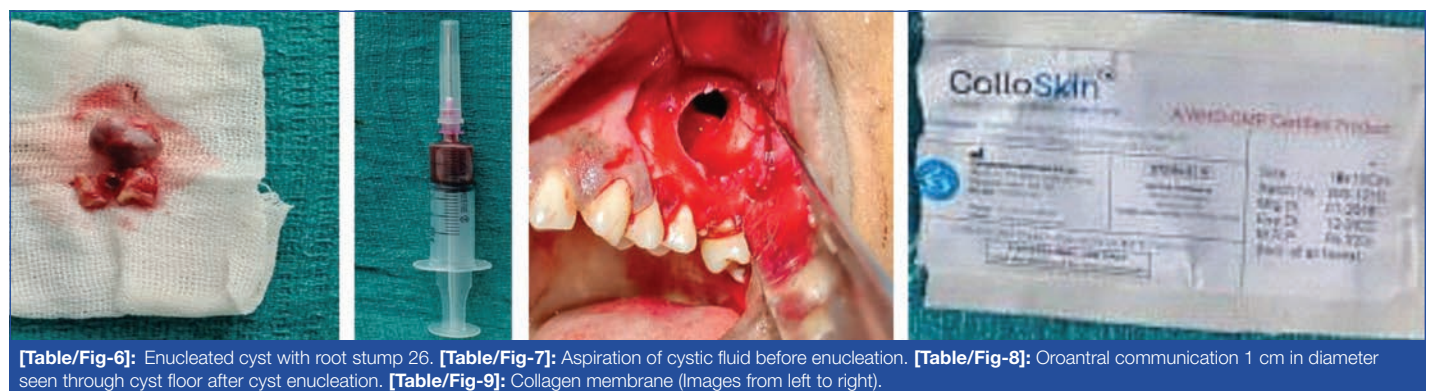
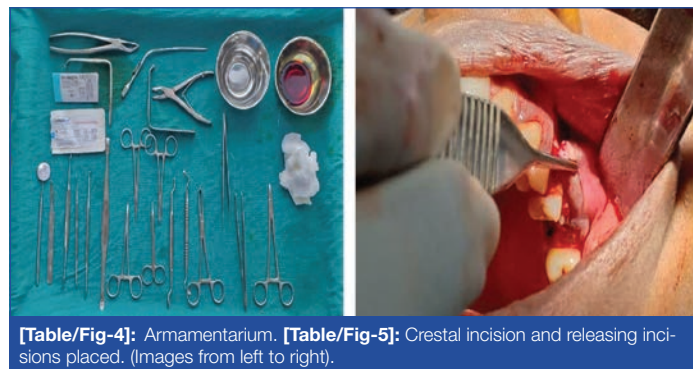
The patient was advised for Orthopantomogram (OPG). Radiographic examination revealed a round, unilocular, radiolucent lesion in the periapical region of the root stump 26 with close approximation with 24, 25 teeth and close to the maxillary sinus floor. The size of radiolucency measured about 3 cm in diameter and was lined by a thin line of radiopacity. Based on clinical and radiographic findings, a provisional diagnosis of periapical cyst was made [Table/Fig-3].



[Table/Fig-1]: Extraoral swelling of left side of the cheek and obliteration of nasolabial fold. **[Table/Fig-2]:** Intraoral swelling in relation to 24,25 apical region obliteration of buccal sulcus. **[Table/Fig-3]:** Radicular cyst involving left maxillary sinus with clear radiopaque borders in relation to 26 root stump region. (Images from left to right)

Surgical procedure: Antibiotics and analgesics were prescribed preoperatively i.e., amoxicillin 250 mg three times daily and metronidazole 500 mg twice daily and diclofenac with paracetamol twice daily and serratiopeptidase 20 mg three times daily started prior to surgery to control infection. Patient was planned for enucleation under local anaesthesia. Informed consent was obtained prior to the surgery. Patient was painted and draped under sterile environment with proper armamentarium [Table/Fig-4]. Intraoral irrigation with betadine done before local anaesthesia to reduce bacterial population. Left Anterior Superior Alveolar (ASA) nerve block, infraorbital nerve block were given with local anaesthetic (2% lignocaine with adrenaline 1: 80,000). Crestal incision with Bard Parker (BP) blade no. 15 was placed with anterior, posterior releasing incisions made intraorally between teeth 24 to 27 [Table/Fig-5]. Full thickness mucoperiosteal flap was raised. Careful elevation of flap from the cystic wall helped unnecessary perforation and exudation of cystic fluid from the cyst. Cystic wall was identified and removed completely along with the associated root stump 26 and aspiration of cystic fluid [Table/Fig-6,7]. Since, there was a close approximation of cyst wall with the maxillary sinus, an oroantral communication was inadvertently created during enucleation and the communication defect was measured around 1 cm, approximately [Table/Fig-8]. The defect was planned to be reconstructed with gelfoam and collagen membrane, immediately.

A bovine collagen membrane 10×20 cm, brand name CollonSkin™ by Colo Genesis Healthcare Pvt. Ltd. was used [Table/Fig-9].



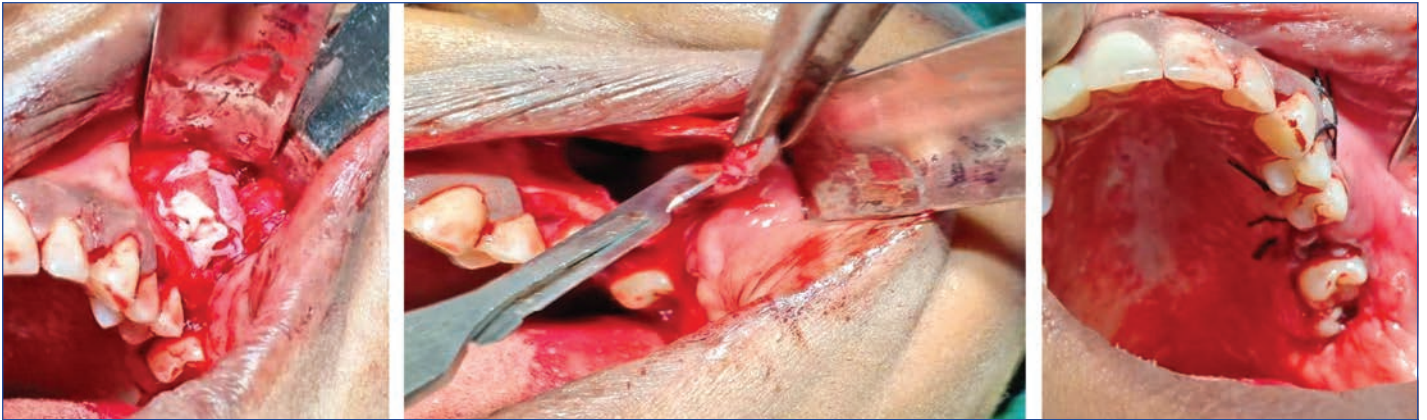
Absorbable gelatin sponge AbGel from Sri Gopal Krishna labs was used [Table/Fig-10]. This gelatin is made of non toxic, non allergenic, non immunogenic, non pyrogenic material. Collagen membrane was covered the gelfoam in a pom-pom shape [Table/Fig-11,12] and then placed in front of the defect to close the oroantral communication [Table/Fig-13]. It was ensured that this pom-pom shaped material diameter was larger (made manually) than the defect so that it would not slip into maxillary sinus. This was the most important factor considered, when processing the pom-pom pack. Gelfoam gave bulk to the material and collagen membrane helped to increase wound healing and arrest bleeding from surrounding soft tissue and primary closure was done with buccal advancement flap with 3-0 Mersilk [Table/Fig-14,15]. Patient developed inflammatory oedematous swelling on 1st postoperative day which subsided after 3rd postoperative day. The patient was followed-up every month for signs of infection, allergy at wound site for 6 months. There was no infection after 6 months of follow-up [Table/Fig-16] and clinically significant bone formation occurred at oroantral communication area which was confirmed by OPG [Table/Fig-17]. Intraoral wound healed with good soft tissue cover at 26 region [Table/Fig-18].

Histopathological report revealed a cystic lesion characterised by non specific epithelial lining which ranged from hypoplastic to ulcerative. The connective tissue was inflamed and showed occasional bland epithelial nests. The connective tissue also showed cholesterol clefts and giant cell reaction and peripheral residual bone consistent with odontogenic cyst [Table/Fig-19].

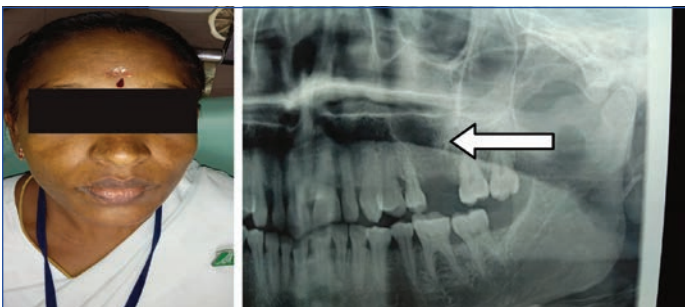
DISCUSSION

Oroantral communication can occur due to extraction of posterior teeth (92.63%), enucleation of cysts, tumours (4.4%), maxillofacial trauma (1.3%), periodontal infections (0.93%) [1-3] as well as due to tuberosity fracture, implant displacement into maxillary sinus, osteonecrosis, mucormycosis, flap necrosis, failure of Caldwell-Luc operations [4-6].

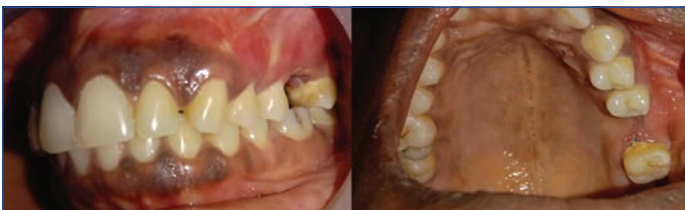In the present case report, OAC was created during enucleation of periapical cyst which was in close approximation with maxillary sinus. Acute maxillary sinusitis can develop from larger, untreated defects in



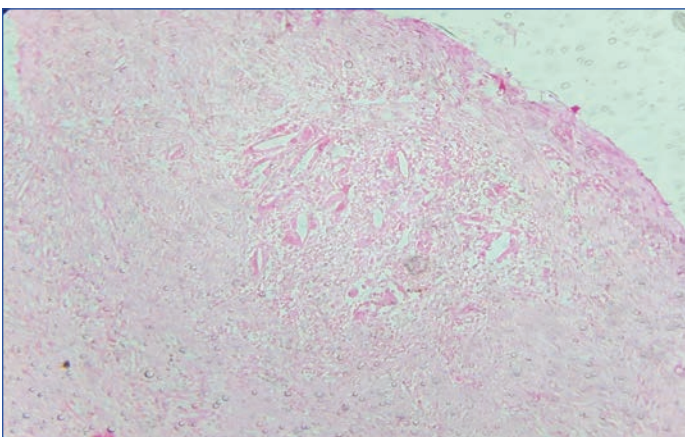
[Table/Fig-13]: Collagen membrane and gelfoam pom-pom ball was placed on the 1 cm opening of the oroantral communication on the floor of the cyst to close the opening. **[Table/Fig-14]:** Flap was closed with buccal advancement flap technique. **[Table/Fig-15]:** Buccal advancement flap was tightly sutured with palatal flap with 3-0 silk (Images from left to right).



[Table/Fig-16]: Postoperative follow-up 6 months with no infection. **[Table/Fig-17]:** Postoperative follow-up 6 months OPG showed complete bone formation at 26 region of oroantral communication area with no infection (Images from left to right).



[Table/Fig-18]: Intraoral view was taken after 6 months follow-up with no infection.



[Table/Fig-19]: Histopathological Image of the odontogenic cyst showing hypoplastic epithelial lining with inflamed connective tissue stroma. Few areas also showing cholesterol clefts (H&E, 40X).

50% of patients within 48 hours and 90% of patients within two weeks. Usually 2 mm of oroantral communication can heal spontaneously, without need of any treatment. All these defects have to be closed within 24 to 48 hours otherwise chronic sinusitis, oroantral fistula can develop [5,7]. Surgical closure of OAC is determined by many factors such as, location, size of oroantral communication, alveolar ridge height, maxillary sinusitis, patient medical condition. Oroantral communication should be closed within two weeks to avoid any surgical and medical complications, but, if immediately closed within 24 to 48 hours it has high success rate such as 95% [6]. It was true

in the present case report, where OAC was closed, immediately after it was inadvertently created and good results were achieved. If the defect is not closed immediately, it can lead to maxillary sinusitis due to ingress of food and saliva contamination [8]. Important points to be remembered during closure of maxillary sinus are to close the sinus without infection and tension free closure. When deciding how to treat an OAC, several aspects should be taken into account like the size of the communication, the time of diagnosis and the presence of an infection. Furthermore, the selection of the treatment strategy was influenced by the amount and condition of the tissue available for repair. The size and location of the defect help in picking up the appropriate treatment. Multiple surgical flaps options are available for the management of OAC but, the sliding buccal flap is most commonly used to close OAC when the fistula is located mesially [9].

In the case of a small OAC, suturing the gingiva might be sufficient to close the perforation. When this does not provide adequate closure, a flap procedure is the treatment of choice. As described by Awang MN, flap procedures can be divided into local flaps and distant flaps [10]. There are several techniques to close oroantral communication such as buccal fat pad with pedicle or non pedicle, collagen membrane, autografts, and allografts and xenografts [11-13]. Mellonig JT used guided tissue regeneration to close the oroantral communication [13]. Ebenezer V et al., performed dean's technique where demonstrated small defects with buccal sulcus was not disturbed and minimal postoperative swelling [14]. Buccal fat flap was another surgical technique for closing small-sized to medium-sized oroantral fistula. This flap was called the pedicled buccal fat pad, which was first described by Egyedi in 1977. The tissue was fixed into bone with bur holes or screws and into adjacent palatal and buccal mucosa with resorbable sutures. The exposed buccal fat pad epithelialised in 4 to 6 weeks. A surgical splint was secured to protect the flap [15]. Complications of this technique include necrosis of fat and visible changes in facial contour, when the buccal fat pad is used for reconstruction of large defects, but it is rare case.

Gelfoam is a water insoluble, haemostatic device prepared from purified porcine skin gelatin, and capable of absorbing up to 45 times its weight of whole blood [16]. It increases the size of the gelatin sponge and increase the absorptive capacity of the gelatin, its mechanism of action is mechanical by arresting bleeding when the sponge directly contacts blood surface and caused stasis of blood which caused the blood to coagulate [17]. The maxillary sinus occupies a major part of the body of the maxilla, normally extending into the alveolar process adjacent to the apices of the posterior teeth. Using gelfoam with collagen membrane has more advantages such as collagen membrane covers gelfoam like pom-pom so that gelfoam would not slip into the maxillary sinus [17]. The pom-pom size 1.5 cm in size was used so that it would not disappear inside the 1 cm opening of oroantral communication. Gelfoam gave bulk to the material and helped to form a bridging material between sinus and oral cavity and it caused expansion and arrested the bleeding from the cystic cavity. Gelfoam acted like a haemostatic

and formed matrix for the blood clot and helped bone formation between sinus and oral communication and it was resorbed within 4 to 6 weeks once its purpose fulfilled. This technique was selected because of its easiness and simplicity as it did not require any bone grafts from intraoral and extraoral sites, thereby avoiding donor site morbidity. This technique did not need any soft tissue grafts such as pedicle buccal fat pad because the oroantral communication was 1 cm in diameter. Patient co-operation, regular postoperative care with proper oral hygiene measures were important for successful outcome. Collagen membrane also helped the complete healing of the overlying buccal advancement flap without wound dehiscence.

CONCLUSION(S)

Oroantral communication after maxillary cyst enucleation is always a challenge to Oral and Maxillofacial Surgeons and the success rate is based on the location, size of the defect, type of soft tissue and hard tissue grafts, surgeons' skills, patient co-operation. The present case report shows, how the accidentally created oroantral communication after the maxillary periapical cyst enucleation was closed immediately, intraoperatively time without the use of autografts. The combination of gelfoam and collagen membrane is easily available allograft material which can be used for accidental communication between maxillary cyst and oral cavity during cyst enucleation, and there is no need of special pedicle local grafts to close the communication and this technique is simple, easy to learn and even an inexperienced surgeon will be able to perform this procedure without any complications.

REFERENCES

- [1] Norman JE. Oroantral fistula. Australian Dental Journal. 1977;22(4):284-88.
- [2] Abrahams JJ, Berger SB. Oral-maxillary sinus fistula (oroantral fistula): Clinical features and findings on multiplanar CT. American Journal of Roentgenology. 1995;165(5):1273-76.
- [3] Franco-Carro B, Barona-Dorado C, Martinez-Gonzalez MJS, Rubio-Alonso LJ, Martinez-Gonzalez JM. Meta-analytic study on the frequency and treatment of oral antral communications. Medicina Oral Patologia Oral Cirugia Bucal. 2011(16)5:e682-e687.
- [4] Hassan O, Shoukry T, Raouf AA, Wahba H. Combined palatal and buccal flaps in oro antral fistula repair. Egyptian Journal of ENT and Allied Sciences. 2012;13:77-81.
- [5] Scattarella A, Ballini A, Grassi FR, Carbonara A, Ciccolella F, Dituri A, et al. Treatment of oro antral fistula with autologous bone graft and application of a non-reabsorbable membrane. Int J Med Sci. 2010;7:267-71.
- [6] Khandelwal P, Hajira N. Management of oro-antral communication and fistula: Various Surgical Options. World J Plast Surg. 2017;6:03-08.
- [7] Haas R, Watzak G, Baron M, Tepper G, Mailath G, Watzek G. A preliminary study of monocortical bone grafts for oroantral fistula closure. Oral Surg Oral Med Oral Pathol Oral Radiol Endod. 2003;96:263-66.
- [8] Borgonovo AE, Berardinelli FV, Favale M, Maiorana C. Surgical Options in Oro-antral Fistula Treatment. Open Dent J. 2012;6:94-98.
- [9] Patel R, Patel P, Kalariya V, Patel H, Chavda C. Closure of Oro-Antral Communication Using Buccal Advancement Flap. World J Plast Surg. 2019;8(2):262-64.
- [10] Awang MN. Closure of oroantral fistula. Int J Oral Maxillofac Surg. 1988;17(2):110-15.
- [11] Chaudhary B, Gong Z, Lin Z, Abbas K, Ling B, Liu H. Reconstruction of intraoral maxillary defect with buccal fat pad. J Craniofac Surg. 2014;25(6):2174-77. Doi: 10.1097/SCS.0000000000001075. PMID: 25318441.
- [12] Prasad K, Lalitha RM, Ranganath K, Singh J. Closure of oroantral communication using buccal pad of fat: Report of a case with review of literature. International Journal of Clinical Dentistry. 2011;4(1):87-92.
- [13] Mellonig JT. Enamel matrix derivative for periodontal reconstructive surgery: Technique and clinical and histologic case report. International Journal of Periodontics and Restorative Dentistry. 1999;19(1):08-19.
- [14] Ebenezer V, Balakrishnan, Mohan R, Asir VD. Management of oro antral communication: A review. European Journal of Molecular & Clinical Medicine. 2020;7(2):6382-85.
- [15] Qureshi ZR, Khan M, Din Q. Buccal advancement flap vs palatal rotation flap in the management of oro antral fistula. JKCD. 2012;2(2):54-57.
- [16] Dym H, Wolf JC. Oroantral communication. Oral Maxillofacial Surg Clin N Am. 2012;24:239-47.
- [17] Kamadjaja DB. Closure of oroantral fistula with rotational palatal flap technique. Dent J. 2007;40(1):33-36.

PARTICULARS OF CONTRIBUTORS:

1. Senior Assistant Professor, Department of Oral and Maxillofacial Surgery, Tamil Nadu Government Dental College and Hospital, Chennai, Tamil Nadu, India.
2. Professor, Department of Oral and Maxillofacial Surgery, Tamil Nadu Government Dental College and Hospital, Chennai, Tamil Nadu, India.
3. Senior Assistant Professor, Department of Oral and Maxillofacial Surgery, Tamil Nadu Government Dental College and Hospital, Chennai, Tamil Nadu, India.
4. Senior Assistant Professor, Department of Oral and Maxillofacial Surgery, Tamil Nadu Government Dental College and Hospital, Chennai, Tamil Nadu, India.
5. Postgraduate Student, Department of Oral and Maxillofacial Surgery, Tamil Nadu Government Dental College and Hospital, Chennai, Tamil Nadu, India.

NAME, ADDRESS, E-MAIL ID OF THE CORRESPONDING AUTHOR:

Dr. A Senthil Kumar,
House No. 3, First Floor, Rajive Gandhi Nagar, South Mada Street Extension,
Villivakkam, Chennai-600049, Tamil Nadu, India.
E-mail: drsenthilkumaromfs@gmail.com

PLAGIARISM CHECKING METHODS: [Jain H et al.]

- Plagiarism X-checker: May 06, 2021
- Manual Googling: Sep 17, 2022
- iThenticate Software: Sep 21, 2022 (13%)

ETYMOLOGY: Author Origin

AUTHOR DECLARATION:

- Financial or Other Competing Interests: None
- Was informed consent obtained from the subjects involved in the study? Yes
- For any images presented appropriate consent has been obtained from the subjects. Yes

Date of Submission: **May 05, 2021**
Date of Peer Review: **Jun 15, 2021**
Date of Acceptance: **Sep 19, 2022**
Date of Publishing: **Oct 01, 2022**