

Original Research Article

A multicentre, retrospective and observational study to evaluate safety and functional outcomes of arthroscopic shoulder ligament repair using Sironix suture anchor

K. Vijayaraj¹, V. Rathika², Ashok Kumar Moharana³, Sachin Angrish³, Deepak T. S.^{3*}

¹Department of Orthopaedics, Kumaran Hospitals and Rela Institute, Chennai, Tamil Nadu, India

²Department of Clinical Research, Texas Sports and Sugar clinic, Chennai, Tamil Nadu, India

³Department of Clinical Affairs, Healthium Medtech Limited, Bangalore, Karnataka, India

Received: 15 January 2024

Revised: 28 February 2024

Accepted: 29 February 2024

*Correspondence:

Dr. Deepak T. S.,

E-mail: deepak.ts@healthiummedtech.com

Copyright: © the author(s), publisher and licensee Medip Academy. This is an open-access article distributed under the terms of the Creative Commons Attribution Non-Commercial License, which permits unrestricted non-commercial use, distribution, and reproduction in any medium, provided the original work is properly cited.

ABSTRACT

Background: Arthroscopic shoulder ligament repair is one of the most performed procedures in the orthopaedic specialty. Suture anchor devices are used in arthroscopic surgeries to reattach ligaments or other soft tissues to bone. The goal of this study was to evaluate the safety and functional outcomes after shoulder ligament repair.

Methods: This is a multicentric, retrospective, observational study conducted on patients who underwent primary arthroscopic shoulder ligament tear repair between April 2018 to July 2022, using Sironix suture anchors at Kumaran Hospital and Rela Institute, Chennai, Tamil Nadu, India, and DNV Ortho Care Hospital, Dharmapuri, Tamil Nadu, India. A total of 75 patients were included. Post-surgery measurements of functional outcomes were performed using the PENN shoulder score, simple shoulder test questionnaire, shoulder pain and disability index, and single assessment numerical evaluation. Adverse events were recorded.

Results: At post-surgery follow-up visits, there was a significant improvement in the functional outcomes of all the patients. The PENN shoulder score had a mean (SD) pain score of 92.04 (7.50), a satisfaction score of 91.87 (8.00), and a function score of 93.18 (6.16), respectively. The mean (SD) SST score and SPADI score was 88.9 (9.7), and 2.8 (2.79) respectively. The SANE mean (SD) values of the operated joint and opposite joint were 91.0 (7.31) and 98.1 (4.26) respectively with a p value of 0.0001.

Conclusions: Based on the study results, arthroscopic shoulder ligament repair with Sironix suture anchor resulted in good and desirable functional outcomes with no major adverse events and improved quality of life.

Keywords: PENN shoulder score, Shoulder ligament tear, Soft tissues, Suture anchor

INTRODUCTION

The shoulder is one of the most complex and freely movable joints in the human body. Its unique structure and function facilitate a wide range of motions, but this complexity makes it prone to various types of injuries. The shoulder has four joints, namely, the glenohumeral joint, the acromioclavicular (AC), the sternoclavicular (SC), and

the scapulothoracic joints. There are several ligaments that connect bones and give stability to the shoulder joint.¹ A shoulder ligament tear can be caused by damage to one or more of these ligaments, which may occur because of a severe injury, degeneration, or repetitive strain that may eventually result in pain, joint instability, and a limited range of motion.

Ligament tears can occur at any age and are most often caused by anterior shoulder instability, which results in shoulder dislocation. McLaughlin proposed that after an anterior dislocation, the anterior capsulolabral structures most often fail (Bankart lesion) in younger individuals. Stevens first described the likelihood of a rotator cuff injury following an anterior dislocation in 1926. The overall prevalence of rotator cuff tears following an anterior dislocation range between 7% and 32% and increases with age.² Patients with rotator cuff tears experience a functional impairment of the shoulder that impacts not only their physical health but also their mental and social well-being.³

The shoulder joint is surrounded by the rotator cuff, a collection of four muscles and their tendons. It provides a wide range of motion and keeps the glenohumeral joint stable. Rotator cuff tears occur when tendons in the cuff become partially or completely torn. Causes include overuse, age-related degeneration, traumatic injuries, and repetitive motions. Symptoms include shoulder pain, weakness, or trouble getting to activities.⁴ Rotator cuff tears or ligament tears are the most frequent cause of discomfort and shoulder disability.⁵ A Bankart lesion is described as a tear in the inferior glenohumeral ligament and a separation of the anterior glenoid labrum.⁶ This kind of lesion frequently develops after a severe subluxation, dislocation, or anterior damage. About 87 to 100% of Bankart lesions, 90% of Hill-Sachs lesions, 73% of bony Bankart lesions, and 13% of rotator cuff injuries have been attributed to anterior shoulder dislocations.⁷

Arthroscopic surgery is recommended for patients with ligament tears who fail conservative management or have a high recurrent instability risk. This method diagnoses and treats pathologies that may not be visible through open surgery, resulting in better outcomes, reduced morbidity, and a faster recovery. Recent developments in arthroscopy methods, instrumentation, and implant material play a significant role resulting in better patient outcomes and minimizing failure rates.^{8,9} Over the last few years, the use of suture anchors has emerged as the gold standard for ligament repair.¹⁰ The purpose of the current study is to evaluate the safety and functional outcomes in patients who underwent arthroscopic shoulder ligament tear repair specifically; Rotator cuff repair and Bankart repair using various Sironix suture anchors.

METHODS

This is a multicentric, retrospective, observational study conducted on patients who underwent primary arthroscopic shoulder ligament tear repair between April 2018 to July 2022, using Sironix suture anchors at department of orthopaedics, Kumaran Hospital and Rela Institute, Chennai, Tamil Nadu, India, and department of orthopaedics, DNV Ortho Care Hospital, Dharmapuri, Tamil Nadu, India.

The study included patients who had shoulder ligament tears repaired arthroscopically (Rotator Cuff tears repair or Bankart repair), patients who were between 18 to 80 years of age and who gave written informed consent to participate in the study when attending an in-clinic follow-up visit or providing verbal consent during the telephonic follow-up visit. The study excluded patients who were not responding to calls after three attempts or were not interested in participating in the study, or patients who had experienced traumatic injuries to the same shoulder following the procedure for repairing shoulder ligament tears. The study objectives are as follows: The primary goal is to assess shoulder functionality following arthroscopic shoulder ligament tear repair. The secondary objectives include evaluating post-surgery activity levels, assessing the quality of life after the repair of shoulder ligament tears, and investigating any adverse events associated with the surgery procedure.

All data were collected, and retrospectively reviewed. Data included demographic information (age, height, weight, sex, affected shoulder), characteristics of injury (type of injury, reason for injury, duration of symptoms), pre-surgery laboratory data (X-ray and MRI), previous medical history, additional injuries, adjuvant treatments, and operative complications. Post-surgery patient performance outcome scores were evaluated at follow-up visit using the PENN shoulder score (PSS) a 100-point scale, that evaluates the level of pain, satisfaction, and ability to perform activities of daily living. Simple Shoulder Test (SST) was used to measure the functional limitations of the affected shoulder in patients with shoulder dysfunction. Measurements were made for current shoulder pain and disability using the shoulder pain and disability index (SPADI), and post-shoulder arthroscopy improvements were measured using single assessment numeric evaluation (SANE) scores.

Study implants and its description

Implants used in study were; CEPTRE Knotted UHMWPE suture PEEK anchor (Figure 1), Ceptre Knotted UHMWPE suture Titanium anchor (Figure 2) and STATIV Knotted UHMWPE suture anchor (Figure 3). CEPTRE Knotted UHMWPE Suture PEEK Anchor, CEPTRE Knotted UHMWPE Suture Titanium Anchor and STATIV Knotted UHMWPE suture anchor (Healthium Medtech Limited, India) are intended to be used for soft tissue fixation to the bone.

Sample size determination

In this study, all patients who had undergone arthroscopic shoulder ligament tears repair using Sironix suture anchor between the period of April 2018 to July 2022 at these two centres were included. All corner's sampling was employed. 75 eligible patients were included in the study.




Figure 1: CEPTRE® knotted UHMWPE suture PEEK anchor.



Figure 2: CEPTRE® knotted UHMWPE suture titanium anchor.



Figure 3: STATIV® knotted UHMWPE suture anchor.

Statistical analysis

Statistical analysis was performed using SAS 9.4. To summarize the demographic data, and the surgery details;

descriptive statistics were employed. Data for qualitative factors were reported as percentages and data for quantitative variables were reported as mean±standard deviation. An independent t-test was employed to compare the mean SANE scores between the operated and normal shoulder. A significance level of $p \leq 0.05$ was considered indicative of statistical significance.

RESULTS

Seventy-five patients who underwent arthroscopic shoulder ligament repair were included in the study as per the eligibility criteria. Demographic data from the 75 patients was collected. Average patient age (years), weight (kg), height (cm), and BMI (kg/m^2) were 43.2 (15.1), 69.2 (9.88), 163.3 (17.5), and 24.6 (3.69), respectively (Table 1). Details of the injury are provided in (Table 1).

Table 1: Demographic data of the patients and details of the injury (n=75).

Characteristics	N (%)
Demographic data of the patients	
Age (years)	43.2 (15.1)
Body weight (kgs)	69.2 (9.88)
Height (cms)	163.3 (17.5)
BMI (kg/m^2)	24.6 (3.69)
Details of the injury	
Rotator cuff injury	49 (65.3)
Bankart Lesion	28 (37.3)
Reason for injury	
Traumatic	68 (90.7)
Atraumatic	7 (9.3)
Shoulder injury	
Right	49 (65.3)
Left	26 (34.7)

Table 2: Shoulder arthroscopic surgery details (n=75).

Characteristics	Number of devices used (%)	Number of patients
Shoulder arthroscopy surgery	149	
Type of implant used		
STATIV Knotted UHMWPE suture anchor	64 (85.3)	28
CEPTRE Knotted UHMWPE suture PEEK anchor	2 (2.7)	2
CEPTRE Knotted UHMWPE suture Titanium anchor	83 (110.7)	50

There was a total of 49 (65.3%) rotator cuff injuries and 28 (37.3%) Bankart lesions among the 75 patients. Seven injuries (9.3%) were atraumatic, and sixty-eight (90.7%) were traumatic in nature.

Table 3: PSS assessment by device.

Type of implant used	Number of implants	Parameters		
		Pain Score	Satisfaction Score	Function Score
STATIV Knotted UHMWPE suture anchor (n=28)	64	95.3±5.08	93.9±6.07	95.7±2.69
Ceptre Knotted UHMWPE suture PEEK anchor (n=2)	2	100±0.00	100±0.00	100±0.00
Ceptre Knotted UHMWPE suture Titanium anchor (n=50)	83	90.1±7.81	90.7±8.52	91.8±6.67

Table 4: Post-operative functional outcomes of shoulder ligament surgery (n=75).

Parameters (mean±SD)	Total number of patients				
	Less than 6 months	6 months to 1 year	1 year to 2 years	More than 2 years	Total Duration
SST score	86.3±13.54	86.8±8.77	90.7±8.41	89.6±9.99	88.9±9.71
SPADI score					
Pain score	3.6±4.28	3.7±3.71	3.3±4.25	4.6±5.82	3.7±4.48
Disability score	2.2±1.48	2.2±1.34	2.2±2.27	2.6±2.71	2.3±2.07
Total SPADI score	2.7±2.48	2.4±1.62	2.6±2.91	3.3±3.75	2.8±2.79
SANE score					
Operated side	88.5±8.57	88.4±8.34	92.8±6.04	92.2±6.64	91.0±7.31
Opposite side	96.4±5.05	98.1±3.89	98.6±3.51	98.2±5.29	98.1±4.26
P value	0.0159	0.0001	0.0001	0.0065	0.0001

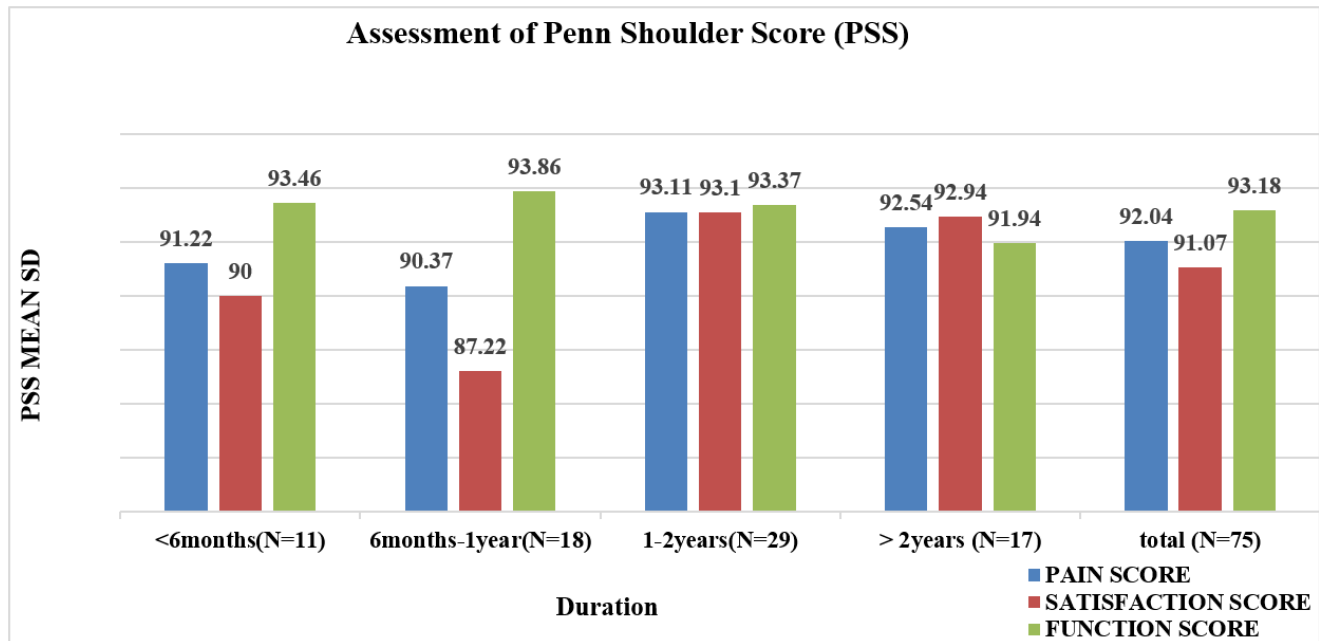


Figure 4: Subjective PENN shoulder scores with pain, satisfaction, and function subscales scores by duration.

Particulars of the shoulder arthroscopy implant surgery and functional assessment

A total of 149 devices were implanted in 75 patients, of which 64 STATIV Knotted UHMWPE suture anchors were used in 28 patients, 2 Ceptre Knotted UHMWPE suture PEEK anchors were used in 2 patients, and 83 Ceptre Knotted UHMWPE suture Titanium anchors were

implanted in 50 patients (Table 2). All functional outcomes (Primary and Secondary) showed good satisfactory values (Figure 4, Table 3-4).

Primary performance outcome

The Penn Shoulder Score consists of three subscales: pain, satisfaction, and function. The pain subscale consists of

three items that address pain at rest, pain with normal activities, and pain with strenuous activities. The satisfaction subscale is assessed with a ten-point numeric rating scale ranging from “not satisfied” with a value of ‘0’ to “very satisfied” with a value of “10”. The function subscale is based on a sum of twenty items.

Interpretation

Figure 4 depicts the overall PSS score for 75 patients. The mean (SD) pain score was 92.04 (7.50), the satisfaction score was 91.87 (8.00), and the function score was 93.18 (6.16).

PSS assessment by device

The mean (SD) pain scores of the STATIV Knotted UHMWPE suture anchor, the CEPTRE Knotted UHMWPE suture PEEK anchor, and the CEPTRE Knotted UHMWPE suture Titanium anchor were 95.3 (5.08), 100.0 (0.00), and 90.1 (7.81), respectively. Similarly, the mean (SD) of satisfaction scores for these anchors were 93.9 (6.07), 100 (0.00), and 90.7 (8.52), and the mean (SD) of function scores were 95.7 (2.69), 100 (0.00), and 91.8 (6.67), respectively (Table 3).

Secondary outcomes

Simple shoulder test score: The levels of activity were measured using the SST Questionnaire. The overall mean (SD) percentage of the SST score was 88.9 (9.7) (Table 4). **Shoulder pain and disability index:** The SPADI scale was used to assess the quality of life after shoulder ligament surgery. The overall mean (SD) of SPADI for 75 patients was 2.8 (2.79). The total mean (SD) of the pain score and disability score were 3.7 (4.48) and 2.3 (2.07), respectively, as shown in (Table 4). **Single assessment numeric evaluation:** After surgery, patients were assessed using the SANE scale to determine shoulder functional improvement, which ranges from 0 to 100, with a higher score being better. The SANE mean (SD) values of the operated joint and opposite joint were 91.0 (7.31) and 98.1 (4.26) respectively with a p value of 0.0001 (Table 4).

Adverse events

Only one patient experienced moderate pain as an adverse event. No serious adverse events or discontinuations were reported.

DISCUSSION

According to Gombera et al patients with continuous pain or limited functionality following a shoulder dislocation frequently have an associated rotator cuff tear. Compared to non-operative therapy, surgical therapy produces better pain alleviation and patient satisfaction. The rotator cuff repair and concurrent capsulolabral lesions contributed to the recovery of shoulder stability.² Arthroscopic shoulder ligament repair is a well-established therapeutic approach

with reliable outcomes.¹¹ The benefits of arthroscopic stabilization include less morbidity, decreased pain, a shorter hospital stay (if necessary), quicker recovery, which in turn facilitates a quicker return to work, in contrast to open procedures.¹² Overall, patients with rotator cuff tears and Bankart lesions had significant improvements in validated subjective outcomes scores with shoulder stabilization. This study focused exclusively on safety and well-established subjective functional outcome measures.

A study by Lenart et al, reported the mean (SD) of the PSS Pain score for more than one year of follow-up as 77.6 (5.3).¹³ According to the current study findings, the PSS Pain score for the same follow-up period was 93.11 (7.56), which was better with a long-term follow-up. Pill et al presented similar findings by conducting a prospective randomized controlled trial involving 64 patients who had arthroscopic rotator cuff repair.¹⁴ A study by DeFranco et al found that patients over two years of follow-up had average PSS satisfaction and function scores of 75.0 (31.0) and 86.3 (14.7).¹⁵

The present study found significantly better functional outcomes for more than two years of follow-up, with PSS pain scores of 92.94 (7.72) and 91.94 (8.13), respectively. A prospective observational study by Lee et al found that at six months of follow-up, the mean (SD) SST score was 62.5 (13).¹⁶ According to the findings of the present study, the mean (SD) STT score at six months to one year was 86.8 (8.77), demonstrating substantial improvement in post-surgery activity levels. In the present study, a notable improvement was seen in the SPADI score, including the mean (SD) of the pain scale, disability scale, and total SPADI score were 3.7 (4.48), 2.3 (2.07) and 2.8 (2.79) respectively. Comparable results were found in a study by Carr et al.¹⁷

According to a study by Cvetanovich et al the average SANE score after 1 year following shoulder ligament surgery was 82.5.¹⁸ Another study that assessed short-term results and return to work rates following arthroscopic RCR found that the mean (SD) SANE score was 91.88 (12.30).¹⁹

Another retrospective study by Prathapkumar et al reported a mean (SD) SANE score of 95 (6.7) after 2 years of follow up.²⁰ A study by Bhatia et al reported the mean SANE score as 85.1.²¹ On similar lines, the current study findings showed that the SANE score for more than two years of follow-up was 91.0 (7.31). However, the SANE mean (SD) values of the operated joint and opposite joint were 91.0 (7.31) and 98.1 (4.26) respectively with a p value of 0.0001. This significant difference in the SANE scores between the operated and the unaffected opposite shoulder is not an uncommon finding. Patients may perceive a difference in function between the two shoulders, even if the surgical outcome is deemed successful.²² There was a significant correlation found in PSS, SST, SPADI, and SANE scores regarding the

previously published literature. There were no adverse device effects reported in the study.

Limitations

This study has a few limitations. To begin with, its retrospective nature emphasizes the need for more prospective investigations, ideally involving randomized controlled trials. Furthermore, the study's sample size is comparatively small. Nonetheless, it's important to highlight that the long-term follow-up data presented here, derived from a real-world context, undoubtedly adds a valuable dimension to the study's findings.

CONCLUSION

Shoulder ligament repair with suture anchors provides a predictable improvement in pain and function. The current study devices offer a secure and efficient strategy, resulting in satisfactory postoperative outcomes. Based on the study results, it can be concluded that employing Sironix suture anchors (CEPTRE Knotted UHMWPE suture PEEK anchor, CEPTRE Knotted UHMWPE suture Titanium anchor, and STATIV Knotted UHMWPE suture anchor) in arthroscopic shoulder ligament repair is regarded as safe and effective.

ACKNOWLEDGEMENTS

The authors are thankful to Techsol life sciences for providing medical writing assistance for this manuscript.

Funding: Healthium Medtech Limited, Bangalore, India
Conflict of interest: Authors Ashok Kumar Moharana, Sachin Angrish and Deepak T.S. are employees of Healthium Medtech Limited, India, who are manufacturers of Sironix shoulder implants
Ethical approval: The study was approved by RIPON Independent Ethics Committee

REFERENCES

1. Miniato MA, Anand P, Varacallo M. Anatomy, Shoulder and Upper Limb, Shoulder. In: Stat Pearls. Treasure Island (FL): Stat Pearls Publishing; 2023.
2. Gombera MM, Sekiya JK. Rotator cuff tear and glenohumeral instability: a systematic review. *Clin Orthop Relat Res.* 2014;472(8):2448-56.
3. Rincón-Hurtado ÁM, Rocha-Buelvas A, López-Cardona A, Martínez JW. Health-related quality of life of patients with rotator cuff injuries, Cofee Triangle, Colombia, 2013. *Rev Bras Ortop.* 2018;53(3):364-72.
4. Kirsi P, Jari Y, Hannu K, Arja H. The relationship between functional disability and health-related quality of life in patients with a rotator cuff tear. *Disab Rehab.* 2012;34(24):2071-5.
5. Maruvada S, Madrazo-Ibarra A, Varacallo M. Anatomy, Rotator Cuff. In: StatPearls. Treasure Island (FL): StatPearls Publishing; 2023.
6. Rao AJ, Verma NN, Trenhaile SW. The "Floating Labrum": Bankart lesion repair with anterior capsular extension using 2 anterior working portals. *Arthrosc Tech.* 2017;6(5):e1607-11.
7. Chang LR, Anand P, Varacallo M. Anatomy, shoulder and upper limb, glenohumeral joint. In: StatPearls. Treasure Island (FL): StatPearls Publishing; 2023.
8. Matache BA, Hurley ET, Kanakamedala AC, Jazrawi LM, Virk M, Strauss EJ, et al. Knotted Versus Knotless Anchors for Labral Repair in the Shoulder: A Systematic Review. *Arthroscopy.* 2021;37(4):1314-21.
9. Thangarajah T, Lo IK, Sabo MT. Rotator cuff repair techniques: Current concepts. *J Clin Orthop Trauma.* 2021;17:149-56.
10. Matache BA, Hurley ET, Kanakamedala AC, Jazrawi LM, Virk M, Strauss EJ, et al. Knotted Versus Knotless Anchors for Labral Repair in the Shoulder: A Systematic Review. *Arthroscopy.* 2021;37(4):1314-21.
11. Shim JW, Jung TW, Kim IS, Yoo JC. Knot-Tying versus Knotless Suture Anchors for Arthroscopic Bankart Repair: A Comparative Study. *Yonsei Med J.* 2021;62(8):743-9.
12. Karjalainen TV, Jain NB, Heikkinen J, Johnston RV, Page CM, Buchbinder R. Surgery for rotator cuff tears. *Cochrane Database Syst Rev.* 2019;12(12):CD013502.
13. Lenart BA, Martens KA, Kearns KA, Gillespie RJ, Zoga AC, Williams GR. Treatment of massive and recurrent rotator cuff tears augmented with a poly-l-lactide graft, a preliminary study. *J Shoulder Elbow Surg.* 2015;24(6):915-21.
14. Pill SG, McCallum J, Tolan SJ, Bynarowicz T, Adams KJ, Hutchinson J, et al. Regenesorb and polylactic acid hydroxyapatite anchors are associated with similar osseous integration and rotator cuff healing at 2 years. *J Shoulder Elbow Surg.* 2021;30(7S):S27-37.
15. DeFranco MJ, Bershadsky B, Ciccone J, Yum JK, Iannotti JP. Functional outcome of arthroscopic rotator cuff repairs: a correlation of anatomic and clinical results. *J Shoulder Elbow Surg.* 2007;16(6):759-65.
16. Lee JH, Lee YB. Clinical and radiologic outcomes of combined use of biocomposite and peek suture anchors during arthroscopic rotator cuff repair: a prospective observational study. *J Clin Med.* 2020;9(8):2545.
17. Carr A, Cooper C, Campbell MK, Rees J, Moser J, Beard DJ, et al. Effectiveness of open and arthroscopic rotator cuff repair (UKUFF): a randomised controlled trial. *Bone Joint J.* 2017;99(1):107-15.
18. Cvetanovich GL, Gowd AK, Liu JN, Nwachukwu BU, Cabarcas BC, Cole BJ, et al. Establishing clinically significant outcome after arthroscopic rotator cuff repair. *J Shoulder Elbow Surg.* 2019;28(5):939-48.
19. Green CK, Scanaliato JP, Dunn JC. Rates of return to manual labor after arthroscopic rotator cuff repair. *Am J Sports Med.* 2022;50(8):2227-33.
20. Prathap Kumar KR, Gopalannair V, Moharana AK, Deepak TS. Clinical and patient reported outcomes after treatment of Rotator Cuff Tears: A Retrospective, Observational Study. *Am J Sports Med.* 2023;18(4):81-5.

21. Bhatia S, Greenspoon JA, Horan MP, Warth RJ, Millett PJ. Two-year outcomes after arthroscopic rotator cuff repair in recreational athletes older than 70 years. *Am J Sports Med.* 2015;43(7):1737-42.
22. Ernstbrunner L, Waltenspül M, Suter C, El-Nashar R, Scherr J, Wieser K. Primary Open Latarjet Procedure Results in Functional Differences but No Structural Changes in Subscapularis Muscle Quality vs the

Healthy Contralateral Shoulder at Long-term Follow-up. *Am J Sports Med.* 2022;50(6):1495-502.

Cite this article as: Vijayaraj K, Rathika V, Moharana AK, Angrish S, Deepak TS. A multicentre, retrospective and observational study to evaluate safety and functional outcomes of arthroscopic shoulder ligament repair using Sironix suture anchor. *Int J Res Orthop* 2024;10:xxx-xx.