

CASE REPORT

One Stage Surgical Management for Third Degree Recto-vaginal Laceration in Mares: A Report of Two Cases

R Pooniya¹, DK Jhamb², R Saini³, Satveer Kumar⁴, SK Sharma⁵

Ind J of Vet Sci and Biotech (2019); 10.21887/ijvsbt.14.4.16

Rectovaginal lacerations in the mare occur during parturition when the foal's limb(s) or head are forced caudal and dorsal. The injury is seen predominantly in primiparous mares and is usually due to violent expulsive efforts by the mare (Colbern *et al.*, 1985; Turner and Mcllwraith, 1989). The injury is also seen following forced extraction of a large fetus or extraction before full dilation of the birth canal. Third-degree perineal lacerations occur when there is tearing through the rectovaginal septum, the musculature of the rectum and vagina, and the perineal body. The communication between the rectum and vagina results in the constant presence of fecal material in the vagina. Reconstruction of third-degree rectovaginal lacerations is necessary to return the mare to breeding soundness. Generally, surgery is not performed on an emergency basis. The torn tissues are edematous and grossly contaminated; and it is advisable to wait a minimum of 4 to 6 weeks before attempting a repair (Turner and Mcllwraith, 1989). Various surgical techniques have been described for repairing this condition, including repairs in one or two stages (Colbern *et al.*, 1985; Belknap and Nickels 1992). This paper describes the six bite suture pattern technique (Goetz technique) for repairing the third-degree rectovaginal laceration in mare in one stage.

History, Clinical Observations, and Surgical Management

Two Marwari primiparous mares were admitted to Veterinary Clinical Complex of the College at Vallabhnagar, Udaipur (Rajasthan) with third-degree rectovaginal lacerations. These injuries occurred during foaling. Upon examination, it was observed that ventral wall of the rectum and dorsum of the vagina were completely torn and there was a common passage for both defecation and urination (Fig. 1). The mares were straining while defecation and urination and showed wind sucking. Tetanus toxoid along with antibiotics, anti-histaminic, and anti-inflammatory drugs were administered. The contaminated and swollen perineal area was cleaned with light povidone-iodine solution.

Surgery was not performed on an emergency basis because the torn tissues were edematous and grossly contaminated. Both the animals were kept off feed and

¹⁻⁵Veterinary Clinical Complex, College of Veterinary and Animal Science, (Rajasthan University of Veterinary and Animal Sciences, Bikaner) Navania, Vallabhnagar Udaipur, Rajasthan, India

Corresponding Author: SK Sharma, Veterinary Clinical Complex, College of Veterinary and Animal Science, (Rajasthan University of Veterinary and Animal Sciences, Bikaner) Navania, Vallabhnagar Udaipur, Rajasthan, India, e-mail: drshivsharmavet@rediffmail.com

How to cite this article: Pooniya, R., Jhamb, D.K., Saini, R., Kumar, S., Sharma, S.K. (2019). One Stage Surgical Management for Third Degree Recto-vaginal Laceration in Mares: A Report of Two Cases. *Ind J of Vet Sci and Biotech.*, 14(4):59-62

Source of support: Nil

Conflict of interest: None

Submitted: 02/04/2019 **Accepted:** 05/04/2019 **Published:** 20/4/2019

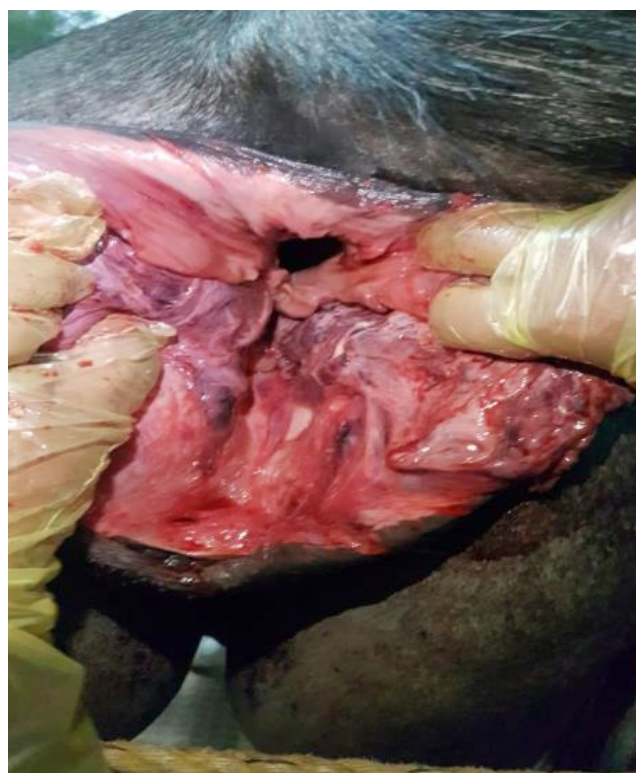

Fig. 1: Rectovaginal laceration in mare

completely on fluid therapy till surgery, i.e., I/V normal saline, Ringer's lactate solution, Dextrose (5%, 25%) BID for 15

days. Within the duration of fluid therapy, fecal material was removed manually to avoid the contamination at the site of laceration. The surgery was performed after 15 days when swelling was completely subsided.

The mares were sedated with xylazine (5–10 mL, slow I/V route). The caudal block was achieved by administrating 5–10 mL Lignocaine HCl in 1st and 2nd intra-coccygeal space. The perineal area was prepared for surgery. The ventral wall of the rectum and dorsum of the vagina were separated so that separate shelf for rectum and vagina can be prepared. After making shelves for rectum and vagina, the torn rectum and vagina were sutured by six bite technique (Goetz technique for one stage repair) using polyglyconate no. 1 (monofilament absorbable suture, Maxon™). The first bite was placed in the left vaginal flap (ventral to dorsal), the second bite in the left rectal flap (ventral to dorsal), and the third bite in the right rectal flap (dorsal to ventral). The second and third bites remained in the rectal submucosa and did not penetrate the rectal

mucosa. The fourth bite was placed in the right vaginal flap (dorsal to ventral) and exited through the vaginal mucosa. The fifth bite reentered the right vaginal flap (medial to the fourth bite) in a ventral to dorsal direction, and the sixth bite was placed in the left vaginal flap medial to the first bite, in a dorsal to the ventral direction (Fig. 2) (Belknap and Nickels, 1992). When the sutures were tightened then there was a separate passage for rectum and vagina. The operation was completed by reconstruction of the perineum with single interrupted sutures using Polyglactin (Vicryl, Ethicon, USA) no.1 in 2 polyglyconate 3 layers commencing cranially and terminated caudally. The skin of perineum was closed with simple interrupted silk suture No.1 (Trusilk, Sutures India) (Figs 3 and 4).

Postoperatively, the mares were maintained on antibiotics Inj. Ceftriaxone + Tazobactam 3375 mg I/V BID for 5 days, Inj. Avil 10 ml I/M for 3 days, and Inj. Flunixin Meglumine 1.1 mg/kg, I/V once for 3 days. The repaired perineal area was dressed with a light povidone-iodine solution followed by maggoticidal spray for 14 days. The mares were maintained on green grass only to pass loose faeces and to avoid any straining. The silk sutures on the skin of perineum were removed on the 12th postoperative day. The mares started passing urine and faeces through the separate openings after repair. Both mares showed uneventful recovery after 14 days of surgery (Fig. 5).

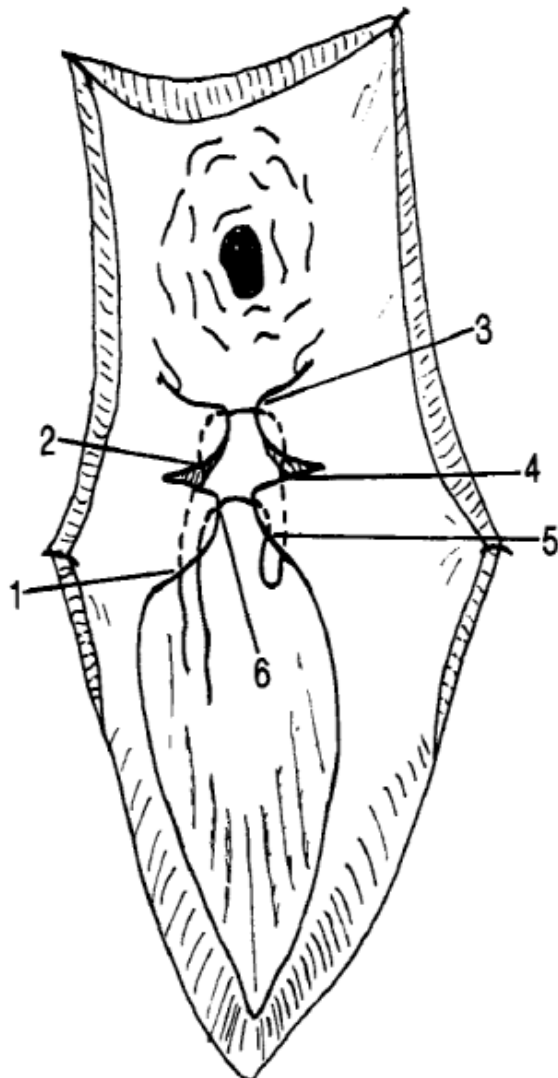


Fig. 2: Goetz six bite suture pattern

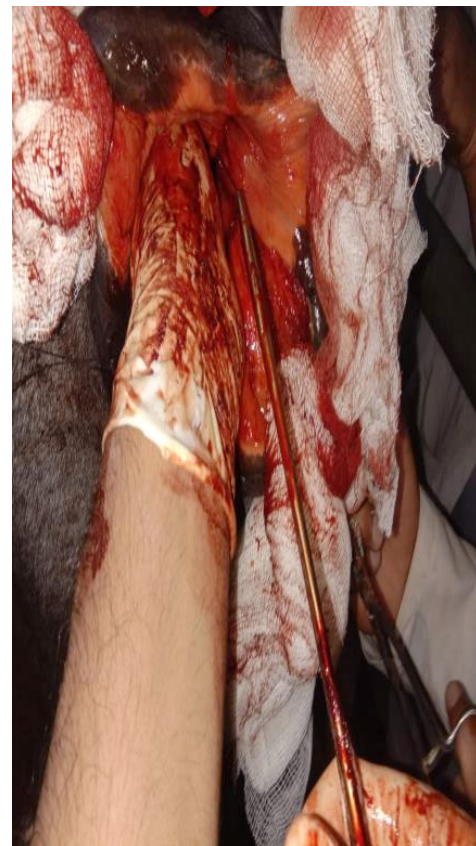

Fig. 3: Intraoperative post-operation

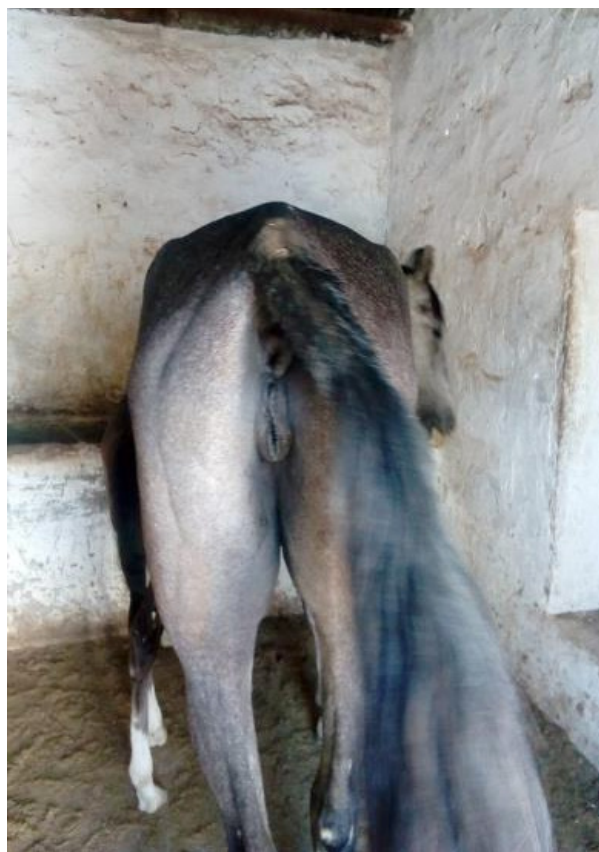

Fig. 5: 2 months

DISCUSSION

A rectovaginal laceration is a serious complication in unattended mares during foaling and is very difficult to manage also. At the site of laceration, there is usually contamination, inflammation, and edema (Singh and Saharan, 2017). First-degree lacerations occur when only the mucosa of the vagina and vulva are involved. Second-degree lacerations occur when the submucosa and muscularis of the vulva, anal sphincter, and the perineal body are involved, but there is no damage to the rectal mucosa. Third-degree perineal lacerations occur when there is tearing through the rectovaginal septum, the musculature of the rectum and vagina, and the perineal body (Anes, 1988).

Surgical management of the perineal laceration includes the timing of the operation and the severity of the tissue damage, particularly with lacerations involving the rectum. The management is divided into two parts: immediate treatment and delayed surgical repair (Woodie, 2006). The repair of the third-degree perineal laceration using a Goetz technique (Six bite pattern) offered considerable promise for single stage repair. Pre-operative and post-operative management of faecal consistency is considered important in perineal surgery in mares. The faeces must remain soft for at least 2 weeks following repair to minimize the pressure required for defecation and thus minimize stress on the suture line (Schonfelder and Sobiraj, 2004; Hospes and Bleul, 2007).

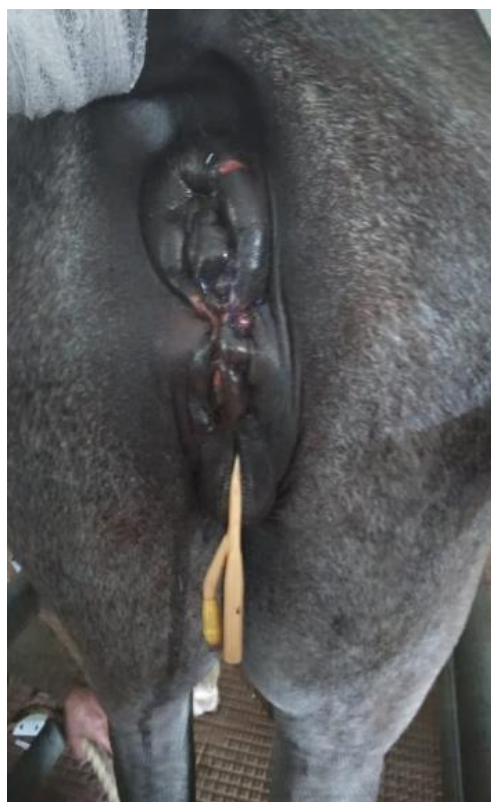


Fig. 4: After operation

Complications of the used method for repair of the third-degree rectovaginal laceration include rectovaginal fistula formation, urine pooling and complete dehiscence of the repair. Wound dehiscence is the most common and serious complication to third-degree rectovaginal laceration repairs and occurs with all techniques. In our report, third-degree rectovaginal laceration in both mares was repaired successfully by Goetz method, and dehiscence of the suture line and fistula formation did not occur.

Advantages of a single stage surgery over a two-stage repair, in which the second phase is done 2–4 weeks later, include less hospitalization, less pre-operative and post-operative care, and a single surgical procedure. However with two-stage repairs, because the anal orifice is larger, the mare can defecate more easily. Also, there is less chance of the rectum's becoming impacted and the mare's straining to defecate, leading to dehiscence or fistulation of the repair (LeBlanc, 1999).

ACKNOWLEDGMENT

Authors thank the Dean of the Navania Veterinary College and University RAJUVAS authorities for clinical facilities provided.

REFERENCES

- Aanes, W.A. (1988). Surgical management of foaling injuries. *Vet. Clin. North Am. Equine Pract.*, 4: 417-438.
- Belknap, J.K. and Nickels, F.A. (1992). A one-stage repair of third-degree perineal lacerations and rectovestibular fistulae in 17 mares. *Vet. Surg.*, 21(5): 378-381.

- Colbern, G.T., Aanes, W.A. and Stashak, T.S. (1985). Surgical management of perineal lacerations and rectovestibular fistulae in the mare: A retrospective study of 47 cases. *J. Am. Vet. Med. Assoc.*, 186: 265.
- Hospes, R. and Bleul, U. (2007). The effect of extended preoperative fasting in mares undergoing surgery of the perineal region. *J. Equine Vet. Sci.*, 27: 542-545.
- LeBlanc, M.M. (1999). Diseases of the vagina, vestibule and vulva. In: Colahan, P.T, Mayhew, I.G. Merritt, A.M. and Moore, J.N. (Eds.), *Equine Medicine and Surgery*. (5th edn.), St. Louis, Mosby., pp:1175-1193.
- Schonfelder, A.M. and Sobiraj, A. (2004). A vaginal mucosal pedicle flap technique for repair of rectovaginal fistula in mares. *Vet. Surg.*, 33: 517-520.
- Singh, P. and Saharan, S. (2017). Surgical management of perineal laceration in mares. *MOJ Surgery*, 4(4): 86-87.
- Turner, A.S. and McIlwraith, C.W. (1989). Aanes' method of repair of third-degree perineal laceration. In: *Techniques in Large Animal Surgery*. (4th edn). Wiley Blackwell, pp 169-174.
- Woodie, B. (2006). The vulva, vestibule, vagina and cervix. In: Auer, J.A. and Stick, J.A. (Eds.) *Equine Surgery*. (3rd edn.), Philadelphia, W.B. Saunders Co., pp: 845-852.

